

Ocular Toxicity from Pesticide Exposure: A Recent Review

Kushik JAGA^{1,2} and Chandrabhan DHARMANI³

¹Mount Sinai School of Medicine, Department of Psychiatry, New York

²VA Hudson Valley Health Care System, Research and Development, Montrose, New York

³School of Public Health, New York Medical College, Valhalla, New York

Abstract

Toxic effects on eyes result from exposure to pesticides via inhalation, ingestion, dermal contact and ocular exposure. Exposure of unprotected eyes to pesticides results in the absorption in ocular tissue and potential ocular toxicity. Recent literature on the risks of ocular toxicity from pesticide exposure is limited.

Ocular toxicity from pesticide exposure, including the dose-response relationship, has been studied in different animal species. Cholinesterase enzymes have been detected in animal ocular tissue, with evidence of organophosphate-induced inhibition. Pathological effects of pesticides have been observed in conjunctiva, cornea, lens, retina and the optic nerve. Pesticide exposure has been associated with retinopathy in agricultural workers and wives of farmers who used pesticides. Saku disease, an optico-autonomic peripheral neuropathy, has been described in Japan in people living in an area where organophosphates were used. Pesticide exposure is also associated with abnormal ocular movements.

Progressive toxic ocular effects leading to defective vision are a serious health concern. Agricultural workers are at high risk of exposure to pesticides and associated ocular toxicity. Primary prevention is the appropriate method of protecting eyes from pesticide-related damage. This includes improved eye safety and care in workplaces, and effective pesticide regulation for maintenance of public eye health.

Key words: pesticides, eyes, toxicity, vision, protection

Introduction

Health risks associated with pesticide exposure are well known environmental health issues. Pesticide exposures occur in both occupational and non-occupational settings. The most common routes of exposure to pesticides are inhalation, ingestion, and dermal contact (1, 2). Another less common route of entry for toxic pesticides is ocular exposure. This has been reported in scientific literature (3), including a case report (4). The major pesticide groups are insecticides, herbicides, fungicides, and plant growth regulators. The organophosphates (OP), organochlorines, and carbamate insecticides are more widely used pesticides than others (1, 2, 5).

Ocular pesticide exposure involves the direct entry of these chemicals into the eye tissue. These exposures could also

occur from accidental splashes of these chemicals that enter the eye. As a result, these chemicals are absorbed through the eye tissue and enter the circulation. Radioactive studies using β radiation have confirmed the transport of a carbamate insecticide from the cornea, through the aqueous humor, and vitreous humor to the retina (6).

Occupational exposures to pesticides mainly occur in the agricultural sector, which include pesticide applicators, farmers, and other agricultural workers (1, 7, 8). Regular exposure to pesticides with lack of personal protective equipment is a potential health risk, especially to unprotected eyes. Handling of pesticides and subsequent hand-to-eye contact increases the probability of ocular exposure in workers. This may also be caused by improper practices with the lack of washing hands. Aerial spraying of pesticides into the environment over farms also increases the risk of ocular exposure in workers on the ground (9). Ocular exposure to pesticides can occur in non-occupational accidental circumstances in the general population. Environmental exposure to high concentrations of pesticides has resulted in ocular irritation in 99% of affected persons (10). The tragic incident in Bhopal, India in 1984, was caused

Received Nov. 24, 2005/Accepted Jan. 30, 2006

Reprint requests to: Dr. Kushik JAGA

51 Eiler Lane, Irvington, New York 10533, USA

TEL: (914)693-7668, FAX: (914)788-4339

E-mail: Kushik.Jaga@med.va.gov

by an environmental gas leak from a pesticide manufacturing plant that resulted in severe eye casualties in the surrounding community (11, 12).

Toxic effects of pesticides on eyes are known to occur in the exposed individuals by various routes of entry, including ocular exposure. In animal experiments, oral exposure to organophosphates in dogs has resulted in localized pathological changes in the eye tissue (13). The most commonly described effects of pesticides on eyes are; irritation, burning sensation, itchiness, blurring of vision and watering of eyes (3, 14–17). Blurring of vision and burning sensation are known symptoms of OP poisoning from systemic exposure as a result of inhalation, ingestion, or dermal contact (1, 2, 5).

Long-term ocular exposure to pesticides may produce chronic effects in the eyes. Beyond the description of eye symptoms, there is an understanding that pesticides may produce toxic effects on various components of the eye. These include effects on the conjunctiva, cornea, iris, lens, retina, and the optic nerve, including visual neural pathways extending from the brain.

Toxic injury to eyes from pesticide exposure could pose a serious health risk. There is paucity of recent literature and research on ophthalmic complications from pesticide exposure. Therefore, this paper is a review of the extent of damage to the eye including visual defects from exposure to pesticides. For public health reasons, it is crucial to protect the eyes from toxic pesticide exposures, since these chemicals are used globally.

Ocular Toxicity

For this review, published articles on ocular toxicity from pesticide exposure in humans were reviewed from PubMed, the National Library of Medicine in the United States of America (18). Key words used were; pesticides, eyes, toxicity, vision, and protection. Articles selected for the review included studies of pesticide toxicity on different anatomical components of the eye (described earlier). These included reports, case studies, and epidemiological studies.

Ocular effects of pesticides have been studied widely in different animal species. Toxicological studies have examined the effects of different pesticides, mainly OPs such as

malathion, ethyl parathion, fenithion, fenitrothion, and ethylthiometon (19). It is known that these OP insecticides inhibit the activity of the enzyme cholinesterase (ChE) in whole blood, serum (pseudo ChE) and red blood cells (acetylChE), which form the basis of OP toxicity (1, 2, 5). Animal studies have shown that both acetyl and pseudo ChEs are present in ocular tissue in the cornea, choroid, iris, retina, and extraocular muscles, which have higher levels of acetylChE activity (19).

Animal studies on pesticide-related ocular toxicity have also examined the effects of different doses of OPs, and duration of exposure in establishing a dose-response relationship (13, 19). Toxic effects in these studies were assessed by studying pathological effects on ocular tissue using electron microscopy, electroretinography (ERG), and ophthalmoscopic examinations. It was observed that the OP insecticides produced degeneration of the ciliary body, optic neuropathy, and degeneration of the retina and extraocular muscles in animals. Since these studies were specifically conducted to analyze ocular toxicity, lower levels of all ChEs were detected in ocular tissue (19).

In humans, general toxic effects of pesticides on the eyes are symptomatically classified as mainly external, resulting from direct ocular exposure. Subsequent absorption of pesticides in the ocular tissue causes toxic effects. Some of these may be observed clinically or by following specialized eye tests. Chronic exposure to pesticides is also likely to cause further damage to the eye, which may only be considered when visual symptoms are reported (See Fig. 1).

Table 1 shows that exposure to various pesticides by different routes of entry including ocular exposure results in toxic effects on specific anatomic components of the eye. This information was retrieved from the studies selected for the review.

The conjunctiva, which has a greater surface area than other parts of the eye, reacts to chemical injury, with inflammation, congestion, or edema (chemosis). This is usually observed as redness or hyperemia in exposed eyes (3, 4). In agricultural workers exposed to the plant growth regulator, hydrogen cyanamide, its use has been reported to have caused conjunctivitis with ocular hyperemia (14). Acute conjunctival reactions are also caused by delayed irrigation of the eye (3).

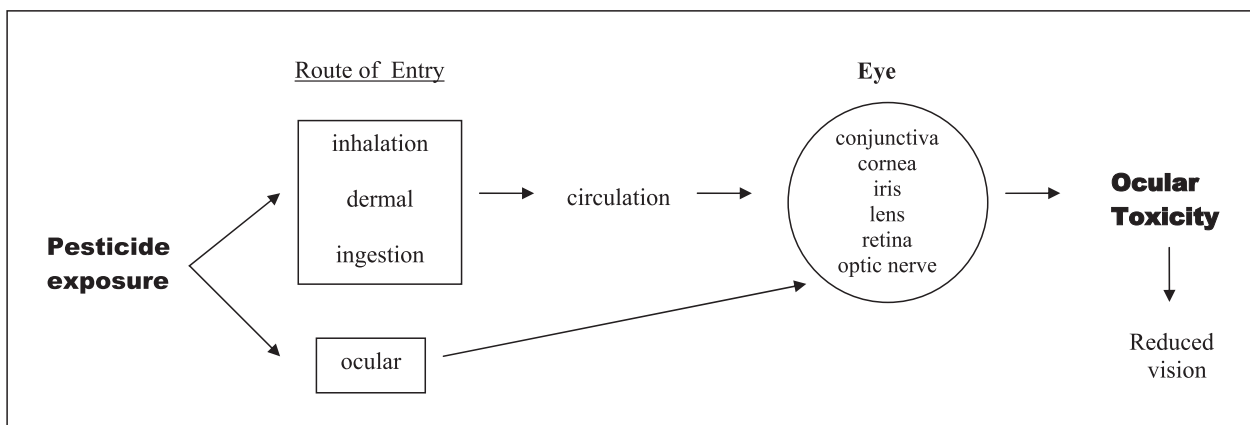


Fig. 1 Diagram showing the toxic effect of pesticide exposure on eyes.

Table 1 Pesticide exposure, routes of entry and ocular toxicity by anatomical component of eye

Chemical	Route of entry (exposure)	Toxic effects by anatomical components of eye	Reference
Insecticides			
Organophosphates	inhalation, dermal, ocular	retinal degeneration optic neuropathy	22* 26*
Malathion	inhalation, dermal	Saku disease	19
Fenthion	inhalation, dermal, ocular	retinopathy	25*
Diazinon	ingestion	ocular motor palsy	28
Carbamate Intermediate (Methyl isocyanate)	ocular	conjunctivitis, corneal opacities, cataract	20, 21
Herbicides			
Paraquat	ocular	conjunctival injury, corneal epithelial defect	4
Glyphosate	inhalation, dermal, ocular	conjunctival, corneal injury	3
Phenoxyherbicide (Agent Orange)	inhalation, dermal	retinopathy	27
Fungicides			
	inhalation, dermal, ocular	retinal degeneration	23*, 24
Plant Growth Regulator			
Hydrogen Cyanamide	ocular	conjunctival injury	14

* Risk of ocular exposure in pesticide applicators.

The cornea, located in the center of the eye, may also be affected by chemical injury. A case report provided description that a farmer exposed to the herbicide, paraquat, developed injury to the cornea, with damage to the epithelium in the acute phase of the eye injury. Over a period of 6 months, the healing of the corneal epithelium was defective with conjunctival type of epithelia. Clinically, the farmer suffered from a decreased visual acuity, which gradually improved over a period of 6 months (4).

Methyl Isocyanate is an intermediate chemical in the production of carbamate pesticides that was released into the environment in the Bhopal Gas tragedy. This chemical disaster caused widespread toxic effects on the health of communities in Bhopal, especially eye toxicities. Initial effects were acute problems with eye irritation, conjunctivitis, watering of eyes, and visual problems (11, 12). Follow-up studies demonstrated that Bhopal survivors had increased incidences of chronic conjunctivitis, eyelid infections, cataracts, corneal opacities, and refractory errors (20, 21).

Pesticide exposure and retinopathies have been studied in animals and humans. Kamel et al. studied retinal degeneration (22). Using a structured questionnaire, licensed pesticide applicators were interviewed for the use of pesticides, and for the symptoms of retinal degeneration. There was a significant risk of retinopathy in pesticide applicators who had used fungicides (OR=1.8, 95% CI=1.3–2.6), and also a lower risk from using organophosphate insecticides.

Kirrane et al. studied retinal degeneration in wives of farmers who were pesticide applicators in the United States. More than 30,000 wives were interviewed. Of these, 281 women had a confirmed medical diagnosis of retinal degeneration. Following adjustment for age and state of residence, there was a significant risk of retinal degeneration in women who had used fungicides (OR=1.9, 95% CI=1.2–3.1). In general, pesticide exposure appeared to be associated with retinal degeneration (23, 24).

Scientists in Japan have studied ocular effects of pesticide exposure extensively, and described a condition called the Saku disease. This is an optico-autonomic peripheral neuropathy

associated with OP exposure, particularly, malathion, in a community living in an agricultural area of Saku. The condition was first seen in school children who experienced tremendous myopia (near-sightedness) during 1957–1971. Further studies on Saku disease revealed features such as myopia, astigmatism, narrowing of visual fields, reduced vision, abnormal eye movements and pupillary responses, with optic neuritis. Retinal effects of the disease included a progressive state with retinal pigmentary degeneration, papilledema of the optic disc, and poor ERG responses with constriction of retinal vasculature (19).

Since OP exposure was considered to be associated with ocular effects, ChE levels were also studied in people with eye symptoms. With Saku disease, 33% of the 71 children had a 22% reduction in plasma ChE levels and 24% reduction in acetylChE levels. In addition, neurological findings were described as sensorial neuropathy, dysmetria, and abnormal EEG changes. It should be noted that people exposed to the OP insecticides, who presented with visual symptoms did not necessarily have neurological effects (19).

Misra et al. also studied retinal changes in workers exposed to the organophosphate, fenthion. Macular changes were significantly more evident in 19% of the 79 workers compared to the controls (p<0.01). These were characterized by features of perifoveal irregularity of pigmentation, with areas of hypopigmentation. The symptoms reported by these workers were; dislike for bright light, blurring of vision, and narrowing of visual fields (25). Ishikawa's epidemiological study revealed that 64 out of 7,435 (0.86%) farmers had impairment in ocular movements and abnormal contraction of the pupil in response to light, which improved after administration with antidotes of OP poisoning such as atropine, and pralidoxime methiodide (PAM). In the same report, Ishikawa described autopsy findings of a professional organophosphorous sprayer that showed severe retinal degeneration with optic neuropathy and arteriosclerotic changes in heart, brain, and retinal vessels. These features were not entirely explained by ChE enzyme inhibition caused by OPs (26).

Kim et al. studied the effects of exposure to Agent Orange

(phenoxyherbicide contaminated with dioxins) on the health of Korean veterans. It was discovered that veterans exposed to high levels of Agent Orange in Vietnam had a significantly higher incidence of retinopathy than non-Vietnam veterans ($p < 0.01$) (27).

Liang et al. described a case of OP (diazinon) poisoning by ingestion in a 52 year old male, who developed a supranuclear gaze palsy and opsoclonus. In this case, the oculocephalic reflex and Bell's phenomenon were preserved. In addition, his pursuit eye movements were restricted, and the saccadic oscillations were present. It was the first of such cases with both gaze palsy and abnormal eye movements, potentially resulting from imbalance in acetylcholine (ACh) levels (28).

There appears to be limited information on pesticide exposure and associated loss of vision. One study described a case of cortical visual loss as a result of carbamate poisoning (29).

Recent research on public health issues of pesticide exposure and associated ocular toxicity, including the protection of vision, is limited. Eyes are exposed to pesticides as a result of their introduction and handling in the environment for pest-control purposes. Subsequently, complications of pesticide toxicity on the eyes are inevitable. One of the major concerns is diminishing vision and the risk of blindness from pesticide exposure. Scientists and researchers have not comprehensively identified toxic effects of pesticides on the most vital organ for sight, which has a minute and microscopically complex anatomical organization. There has been little focus on the effects of pesticides on eye health.

Current research has shown that pesticides affect different components of the eye. There are many unanswered questions as to whether long-term exposure to pesticides would increase the risk of visual impairment. The toxic effect of pesticides may be progressive, and over time may cause significant damage to the eyes. A major cause of visual impairment is retinal degeneration, whose occurrence is associated with several risk factors, such as age, hypertension, light exposure, smoking, alcohol, and obesity (23, 24). It has been shown that pesticide exposure is also a likely risk factor for the occurrence of retinal degeneration. The attributable risk of exposure to pesticides in the development of retinal degeneration is not known. Pesticide exposure may worsen ocular health, considering age-related visual problems, diabetic retinopathy, cataract, glaucoma, retinal detachment, and eye trauma.

The organophosphate insecticides are the most widely used chemicals, and appear to have been researched in terms of ocular toxicity. It is known that these chemicals inhibit the activity of ChEs at the neuromuscular junction, and produce an acute toxicity with high levels of ACh acting on muscarinic and nicotinic receptors (1, 2, 30). A major ocular manifestation of acute OP toxicity is miosis (constriction of the pupil), and blurring of the vision is also common (1, 2, 5, 30). Since there is experimental evidence of ChEs in the ocular tissue in animals, there may be reason to speculate action of OPs in eye tissues. Hutchins has studied this aspect of ocular toxicity, and has proposed that there may be a cholinergic system in the retina, with ACh as a neurotransmitter. Hence, action of OPs on the eye would be described as that of an anti-ChE

nature, potentially affecting cholinergic neurotransmission in the retina (19). Much more work is required in this field to establish the effect of OPs on a cholinergic neural pathway in the eye.

A major health concern in pesticide-exposed people, who are asymptomatic, is the development of ocular toxicity. Without any specific eye complaint, people may not seek appropriate care, or be investigated with and identified by specialized eye tests. Particularly in work situations, this will apply to asymptomatic employees exposed to pesticides. Hence, employers and occupational health personnel would be unaware of any toxic damage occurring in the eyes of employees. This shows that a large segment of the agricultural community with eye diseases from exposure to toxic pesticides may be undiagnosed. Long-term exposure to pesticides may initially not manifest any toxic effects in the exposed population. There may be pathological effects at the cellular level in the eye, which may take years to progress into a clinical ocular condition. Such processes from toxic pesticide exposure to eyes are potentially the beginning of a burden of eye diseases.

People with occupational exposures to pesticides are the primary group with higher levels of exposure. Pesticide applicators, farmers, and agricultural workers constitute a high-risk group for all routes of exposure to pesticides, including the ocular exposure. The lack of eye protection and poor safety practices are the major causes for toxic exposures to eyes. In the study by the Centers for Disease Control (CDC) on hydrogen cyanamide, it was shown that 14 out of 21 agricultural workers (66%) who had incomplete or no eye protection with goggles or face shields reported increased eye symptoms (14). Accidental spills or splashes of pesticides are also means of exposure to unprotected eyes. The first line of action to chemical injuries in the eye is immediate irrigation and washing of the eye with water. This will prevent further damage to affected eyes (31). An efficient approach to the problem would be primary prevention, which includes good education on eye protection, and increased surveillance with screening of workers for visual problems. An occupational health service with the provision of basic eye tests for visual acuity would be useful. Good occupational health and safety training with the provision of eye protective equipment to pesticide applicators should be implemented in workplaces where pesticides are applied. In many countries facilities for handling of eye emergencies is also a mandatory health and safety requirement in workplaces with the presence of pesticides. Placement of workers to safer work areas, and provision of appropriate eye care for affected workers is necessary. Workers with eye health problems should be referred to appropriate eye clinics for further care.

The effect of pesticide toxicity on the eyes could be worse than imagined. Starting with mild visual problems, conditions could progress to more severe visual impairment, or possibly a total loss of vision. Visual impairment and blindness would certainly lower the quality of life of affected individuals. In addition, there would be contributing emotional and psychological effects with mental health issues. Other social issues would emerge leading to personal isolation, increased dependence on others, and hence higher use of facilities for rehabilitation

of the visually handicapped. Visual impairment would also increase the level of disability, and decreased work productivity. Affected workers would no longer be in a position to continue working at the same level, resulting in job losses and further unemployment and socioeconomic and financial problems.

Further preventive measures of eye toxicity from pesticides would be improved regulation of pesticides at various levels. This should be initiated at the governmental level, and applied to pesticide manufacturing, production, suppliers, buyers, and pesticide-application level. In the United States, the Environmental Protection Agency (EPA) requires ocular testing of organophosphates on animals prior to registration of the chemicals (32). On farms, it is the responsibility of farmers to ensure the safety of the environment for assuring the maintenance of health of the workers. This requires good supervision and appropriate training of the safety personnel overseeing employees. Workers handling pesticides should be subjected to compliance of safety regulations to avoid risks of toxic exposures. Limited regulation of pesticides, lack of education and safety are factors, which would increase the probability of ocular exposures to pesticides in agricultural workers in developing countries (33).

Conclusion

It is vital that more research continues in order to define the type and extent of ocular damage due to exposure to pesticides in various settings and durations. Identification of high-risk populations with ocular exposure to pesticides, monitoring of visual symptoms, and improved and rapid methods of diagnosing eye conditions are major components of pesticide-related ocular toxicity research. Developing a system of reporting eye conditions and data information systems would be a valuable resource for such research. Prospective studies in populations with long-term exposure would be appropriate methods of research for progressive eye diseases related to exposures to pesticides.

Protection of the eyes is a major component of public health and preventive medicine. Pesticide exposure is an environmental health risk factor for eye toxicity and potential eye disorders. Public health professionals should be more aware and active in the prevention of pesticide-related toxic effects on eyes. The objective of eye care is the safety of eyes, protection of vision, and maintaining good eye health. It is vital to prevent pesticide exposures in order to sustain community and public eye health.

References

- (1) Echobichon DJ. Toxic effects of pesticides. In: Klassen CD, Doull J editors. *Cassarett and Doull's Toxicology*. New York: McGraw-Hill; 1996. P. 643–689.
- (2) Sullivan JB Jr, Blose J. Organophosphate and carbamate insecticides. In: Sullivan JB, Krieger GR editors. *Hazardous Materials Toxicology: Clinical Principles of Environmental Health*. Baltimore, Maryland: Williams and Wilkins; 1992. P. 1015–1026.
- (3) Bradberry SM, Proudfoot AT, Vale JA. Glyphosate poisoning. *Toxicol Rev*. 2004;23:159–167.
- (4) Mckeag D, Maini R, Taylor HR. The ocular surface toxicity of paraquat. *Br J Ophthalmol*. 2002;86:350–351.
- (5) Schenker MB, Albertson TE, Saiki CI. Pesticides. In: Rom WN editor. *Environmental and Occupational Medicine*. Boston, Toronto, London: Little Brown and Company; 1992. P. 887–920.
- (6) Budai P, Vamagy L, Somlyay IM, Linczmayer K, Pongraz A. Irritative effects of some pesticides and a technical component on tissue structure of the chorioallantoic membrane. *Commun Agric Appl Biol Sci*. 2004;69:807–809.
- (7) Jaga K, Dharmani C. Sources of exposure to and public health implications of organophosphate exposure. *Rev Panam Salud Publica*. 2003;14:171–185.
- (8) Lessenger LE. The pesticide-exposed worker: an approach to the office evaluation. *J Am Borad Fam Pract*. 1993;6:33–41.
- (9) Ciesielski S, Loomis DP, Mims SR, Auer A. Pesticide exposures, cholinesterase depression, and symptoms among North Carolina migrant farmworkers. *Am J Public Health*. 1994;84:446–451.
- (10) Centers for Disease Control and Prevention (CDC). Illness associated with drift of chloropicrin soil fumigant into a residential area—Kern County, California, 2003. *Morb Mortal Wkly Rep*. 2004;53:740–742.
- (11) DharaVR, Dhara R. The Union Carbide disaster in Bhopal: a review of health effects. *Arch Environ Health*. 2002;57:391–404.
- (12) Dhara R. Health effects of the Bhopal gas leak: a review. *Epidemiol Prev*. 1992;14:22–31.
- (13) Atkinson JE, Bolte HF, Rubin LF, Sonawane M. Assessment of ocular toxicity in dogs during 6 months' exposure to a potent organophosphate. *J Appl Toxicol*. 1994;14:145–152.
- (14) Centers for Disease Control (CDC). Update: hydrogen cyanamide-related illnesses—Italy, 2002–2004. *Morb Mortal Wkly Rep*. 2005;54:405–408.
- (15) Gomes J, Lloyd O, Revitt MD, Basha M. Morbidity among farm workers in a desert country in relation to long-term exposure to pesticides. *Scand J Work Environ Health*. 1998; 24:213–219.
- (16) Lu JL. Risk factors to pesticide exposure and associated health symptoms among cut-flower farmers. *Int J Environ Health Res*. 2005;15:161–169.
- (17) Strong LL, Thompson B, Coronado GD, Griffith WC, Vigoren EM, Islas I. Health symptoms and exposure to organophosphate pesticides in farmworkers. *Am J Ind Med*. 2004;46:599–606.
- (18) United States National Center for Biology Information, National Library of Medicine. National Institutes of Health *Entrez PubMed* database. Available at <http://www.ncbi.nlm.nih.gov/entrez/query.fcgi>
- (19) Dementi B. Ocular effects of organophosphates: a historical perspective of Saku disease. *J Appl Toxicol*. 1994;14:119–129.
- (20) Raizada JK, Dwivedi PC. Chronic ocular lesions in Bhopal gas tragedy. *Indian Ophthalmol*. 1987;35:453–454.
- (21) Anderson N, Ajwani MK, Mahshabde, et al. Delayed and

- other consequences from exposure to methyl isocyanate: 93% follow up of exposed and unexposed cohorts in Bhopal. *Br J In Med.* 1990;47:553–558.
- (22) Kamel F, Boyes WK, Gladen BC, Rowland AS, Alavaria MC, Blair A, Sandler DP. Retinal degeneration in licensed pesticide applicators. *Am J Ind Med.* 2000;37:618–628.
- (23) Kirrane EF, Hoppin JA, Kamel F, Umbach DM, Boyes WK, Deroos AJ, Alvanja M, Sandler DP. Retinal degeneration and other eye disorders in wives of farmer pesticide applicators enrolled in the agricultural health study. *Am J Epidemiol.* 2005;161:1020–1029.
- (24) Alvanja M, Sandler DP. Retinal degeneration and other eye disorders in wives of farmer pesticide applicators enrolled in the agricultural health study. *Am J Epidemiol.* 2005;161:1020–1029.
- (25) Misra UK, Nag NK, Mehra MK, Ray PK. Some observations on the macula of pesticide workers. *Hum Toxicol.* 1985;4:135–145.
- (26) Ishikawa S. Ophthalmopathy due to environmental toxic substances especially intoxication by organophosphorus pesticides. *Nippon Ganka Gakkai Zasshi.* 1996;100:417–432.
- (Article in Japanese)
- (27) Kim JS, Lim HS, Cho SI, Cheong HK, Lim MK. Impact of Agent Orange exposure among Korean Vietnam veterans. *Ind Health.* 2003;41:149–157.
- (28) Liang TW, Balcer LJ, Solomon D, Messe SR, Galetta SL. Supranuclear gaze palsy and opsoclonus after Diazinon poisoning. *J Neurol Neurosurg Psychiatry.* 2003;74:677–679.
- (29) Baban NK, Nunley DL, Borges AS Jr, Roy TM. Human sequelae of severe carbamate poisoning. *Tenn Med.* 1998;91:103–106.
- (30) Kwong TC. Organophosphate pesticides: biochemistry and clinical toxicology. *Ther Drug Monit.* 2002;24:144–149.
- (31) Lusk PG. Chemical eye injuries in the workplace. Prevention and management. *AAOHN J.* 1999;47:80–87.
- (32) Hamemik KL. Proposed protocols for the determination of potential ocular effects of organophosphorus pesticides. *J Appl Toxicol.* 1994;142:131–134.
- (33) Konradsen F, van der Hoek W, Cole DC, Hutchinson G, Daisley H, Singh S, et al. Reducing acute poisoning in developing countries—option for restricting the availability of pesticides. *Toxicology.* 2003;192:249–261.